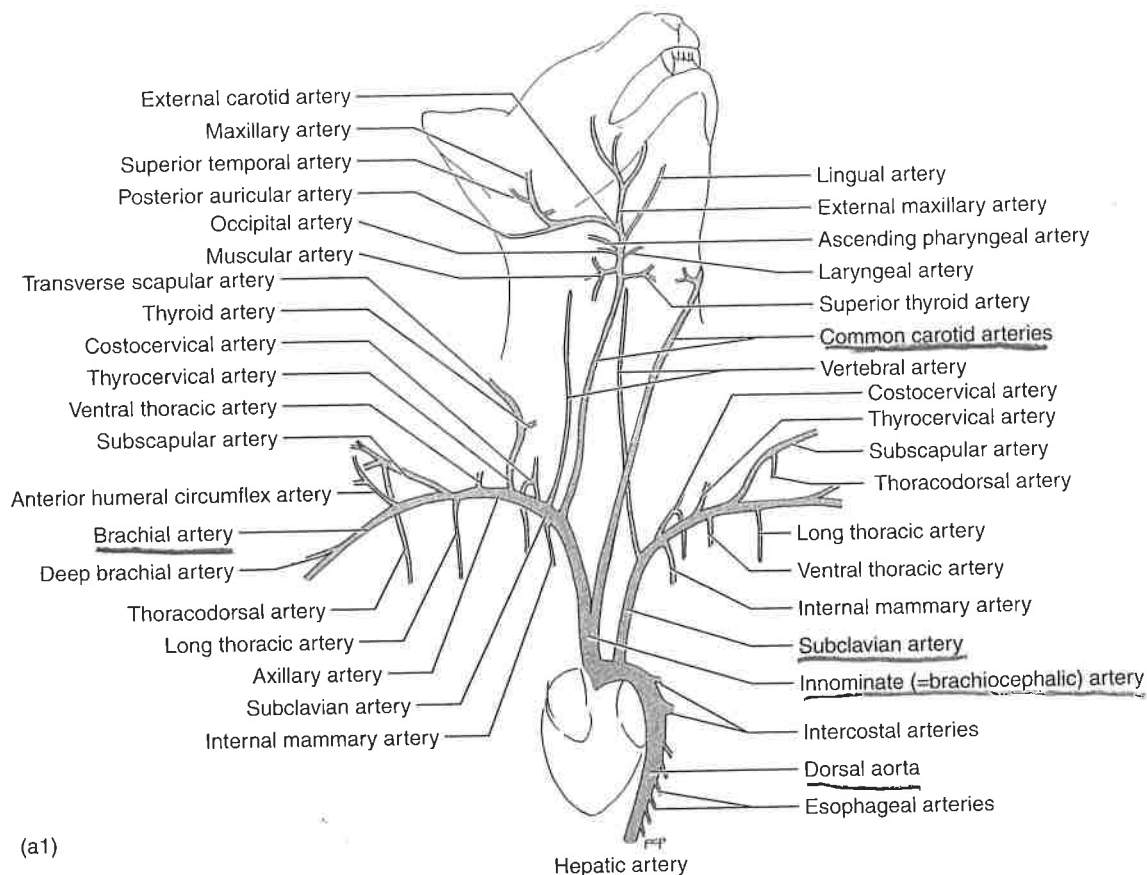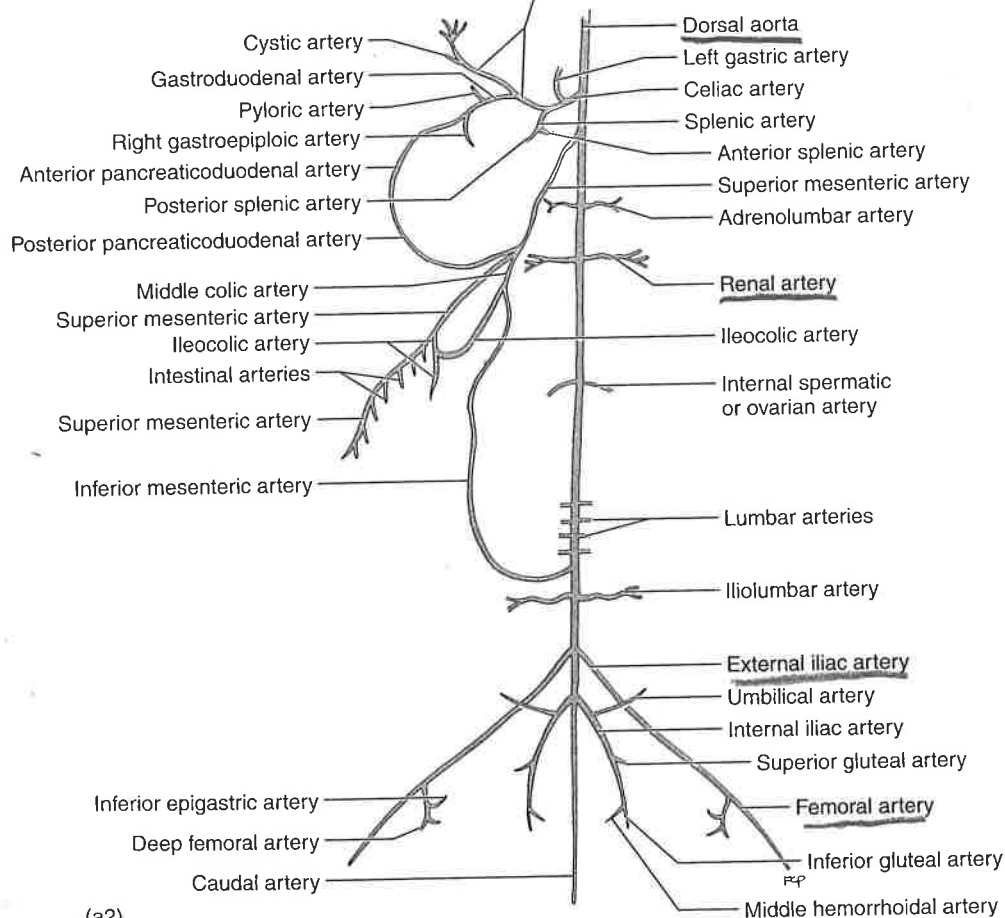


(a1)



(a2)



FIGURE 8.16 Artery (a), vein (b), and hepatic portal vein (c) maps in a cat, ventral view.

